

Diagnosis and Treatment of CORNEAL ULCERATION

Sara Grabiell-Duncan, BS, LVT,
VTS (Ophthalmology)



LEARNING OBJECTIVE:

Readers should gain a basic understanding of the anatomy and physiology of the cornea and diagnosing corneal ulcers. They will also be able to identify potential management options available.

Diagnosis and Treatment

Ulceration of the cornea is one of the most prevalent clinical abnormalities affecting the canine cornea. Diagnosis and treatment of corneal ulceration is not identical for all types of corneal ulcers. An inaccurate diagnosis and improper treatment of corneal ulcers may have profound effects on corneal sepsis, healing, corneal clarity, and ultimately may cause impaired sight, blindness, or even loss of the affected eye. Understanding basic anatomy and physiology of the cornea, its response to injury, recognition of normal corneal wound healing as well as different medical and surgical treatment options is essential to promote healing.

Anatomy

The cornea is composed of 5 distinct layers:

1. **Pre-corneal tear film**—the most superficial (outermost) layer of the cornea is a fluid layer which functions to hydrate, protect and lubricate the cornea, provide nutrition to corneal cells and tissues of the avascular cornea, and maintain optical clarity. The pre-corneal tear film is composed of at least three distinct layers:

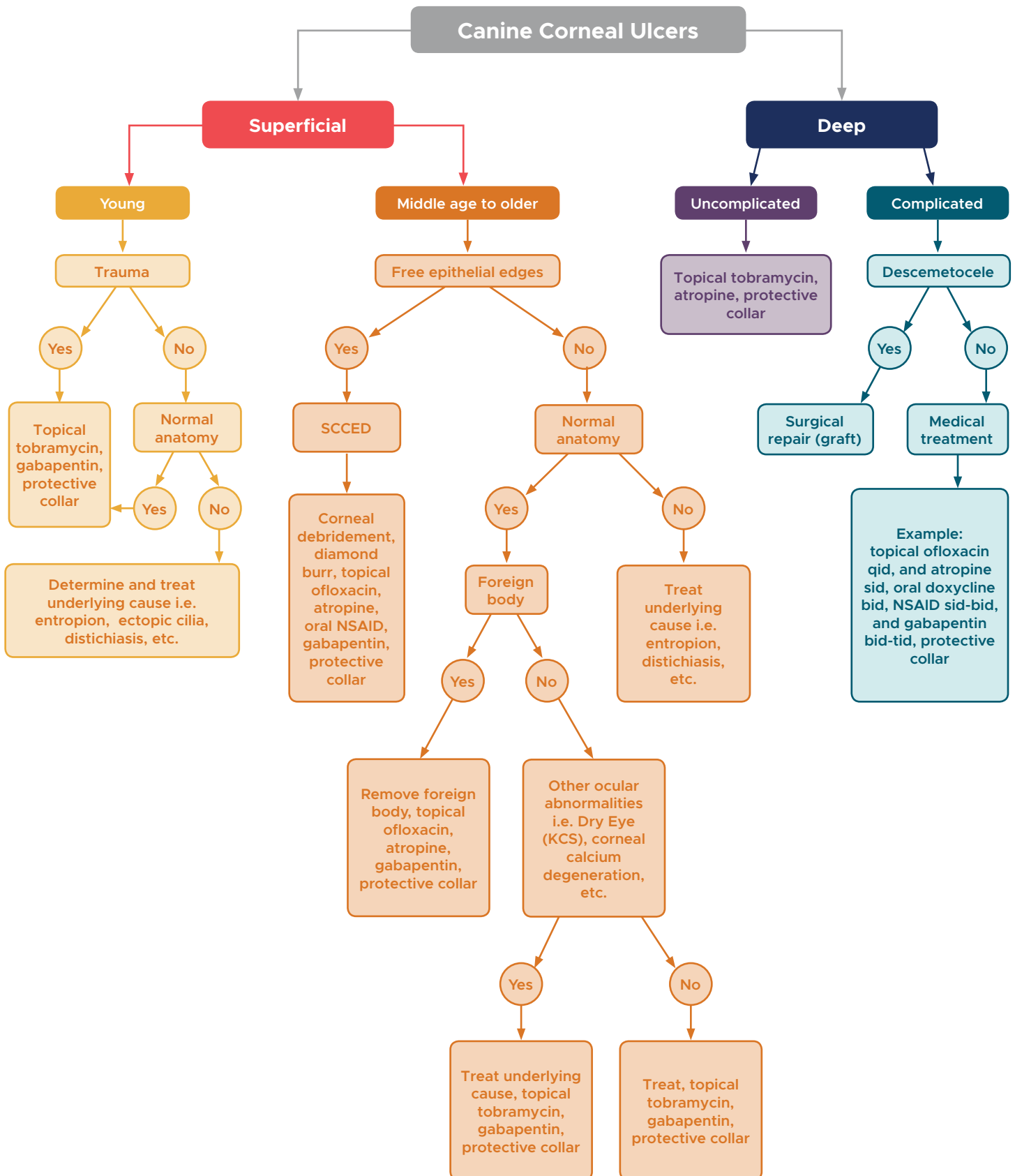
- **Oil layer**—the superficial (outermost) layer consists of oils produced by the meibomian glands located within the eyelids. The oil layer permits the eyelids to move in a gliding action and prevents evaporation of the second (aqueous) layer of the tear film.
- **Aqueous layer**—the aqueous layer constitutes the largest volume of the pre-corneal tear film (95%) and is located between the superficial oil layer and the underlying mucus layer of the pre-corneal tear film. This layer is produced by the orbital lacrimal

gland, which contributes 35-50% of tears and the gland of the nictitating membrane which contributes 35-65% of the aqueous component of tears. This layer is responsible for providing nutrition and oxygen to the cornea and conjunctiva and also functions to keep the epithelium hydrated.

- **Mucoid layer**—the innermost layer of the pre-corneal tear film is composed of mucin and is produced primarily by conjunctival goblet cells. This layer increases the surface area and binds the middle aqueous layer to the corneal surface. (Blinking partially inter-mixes the three component layers of the tear film)

2. **Corneal epithelium and its basement membrane**—the corneal epithelium serves as a barrier to prevent an excessive volume of tear film fluids from entering into the corneal stroma, which maintains relative dehydration of the corneal stroma. The epithelial layer has remarkable regenerative capabilities

This program was reviewed and approved by the AAVSB RACE program for 1 hour of continuing education in jurisdictions which recognize AAVSB RACE approval. Please contact the AAVSB RACE program if you have any comments/concerns regarding this program's validity or relevancy to the veterinary profession.



and re-epithelialization occurs rapidly under normal circumstances. If the entire epithelial layer is removed, it takes approximately 11-14 days to re-epithelialize under normal circumstances.

- 3. Corneal stroma**—the third layer of the cornea is the corneal stroma which is located just underneath the basement membrane of the epithelial layer. The stroma accounts for approximately 90% of the corneal thickness and is composed mostly of uniformly arranged parallel bundles of collagen fibers. The transparency of the cornea is achieved by this precise arrangement of collagen and prevents scattering or refraction of 99% of light entering the cornea. The stroma is extremely hydrophilic (water loving), but absorption of fluids by the stroma is limited by the hydrophobic (water repelling) corneal epithelium (preventing absorption of tear film) and the corneal endothelium (preventing absorption of aqueous humor). Dysfunction or loss of either the corneal epithelium or endothelium may permit over-hydration of the corneal stroma and result in corneal edema.
- 4. Descemet's membrane**—The fourth layer of the cornea is Descemet's membrane, which is the basement membrane of the corneal endothelium. Descemet's membrane is composed of collagen, is highly elastic, and continues to thicken with advancing age.
- 5. Endothelium**—The innermost layer of the cornea is the corneal endothelium which lines the inner surface of Descemet's membrane and is in direct contact with aqueous humor. This layer consists of a monolayer of cells that have a poor regenerative capacity. Endothelial cells are the predominant barrier to the movement of aqueous humor into the corneal stroma and are essential to maintain the transparency of the cornea. The cornea is approximately 0.5 mm thick, is normally avascular, and is relatively

“dehydrated” to maintain optimal optical clarity for refraction of light entering the eye. The cornea is highly innervated by the ophthalmic branch of the trigeminal nerve, thus its exceptional sensitivity. Sensory receptors are concentrated in the superficial (anterior) third of the corneal stroma and in the corneal epithelium. The epithelium contains the greatest density of sensory nerves per square millimeter than any other tissue in the body. It is for this reason that superficial ulcerations or abrasions are more painful than deep ulcerations.

Corneal Erosions and Ulcers

Corneal erosion is defined as loss of corneal epithelial cells without the loss of the epithelial basement membrane. Corneal ulceration is defined as a loss of the corneal epithelium and its basement membrane. Ulceration can also include loss of part or the entire corneal stroma. Solubility properties of the epithelium and stroma help differentiate between ulcerations and erosions. The epithelium acts as a barrier to water-soluble solutions, whereas the hydrophilic stroma acts as a “sponge” to water-soluble solutions. Fluorescein sodium dye is water-soluble—therefore, if an ulcer is present the stroma will retain the dye. If a corneal erosion is present, the fluorescein stain will be partially repelled by the remaining epithelial cell layers. The basement membrane of the corneal epithelium is a weak barrier to prevent water-soluble compounds from entering

Corneal erosion is defined as loss of corneal epithelial cells without the loss of the epithelial basement membrane. Corneal ulceration is defined as a loss of the corneal epithelium and its basement membrane.

the corneal stroma. Depending on the amount of epithelial cellular loss, fluorescein may still enter the corneal stroma. Full-thickness loss of corneal stroma exposes Descemet's membrane which does not retain fluorescein dye.

Corneal ulcers are categorized by their topographic location, depth and etiology. Location of an ulcer is important because it often provides clues to determine the underlying cause. When an ulcer is located in the superior portion of the central cornea, detailed examination of the palpebral surface of the upper eyelid may reveal ectopic cilia or embedded foreign body. A horizontally-oriented ulcer located in the central cornea is suggestive of exposure from incomplete blinking (lagophthalmos). Most traumatic ulcers also occur in the central or paracentral region. If an ulcer is located in the inferior-nasal region, examination behind the nictitating membrane may reveal an embedded or retained foreign body. Ulcers located in the paralimbal region are suggestive of an eyelid conformational abnormality or an eyelash abnormality. Limbal-based ulceration is suggestive of an immune-mediated etiology.

The depth of an ulcer is much more important than the geographic size of an ulcer when determining the severity of corneal ulceration. A superficial ulcer is an ulcer only involving the epithelium and its basement membrane. When an ulcer involves less than one third of the stroma, it is classified as a superficial stromal ulcer, and if it involves more than one third of the stroma, it is classified as a mid to deep stromal ulcer. Full-thickness loss of corneal stroma exposes Descemet's membrane and is called a descemetocele. A perforated corneal ulcer occurs when Descemet's membrane ruptures, resulting in leakage of aqueous humor from the anterior chamber.

Indisputably, there is always an underlying cause of corneal ulceration—determining the primary origin may be difficult, but is an absolute necessity. Besides using location and depth to help determine the primary cause of ulceration,

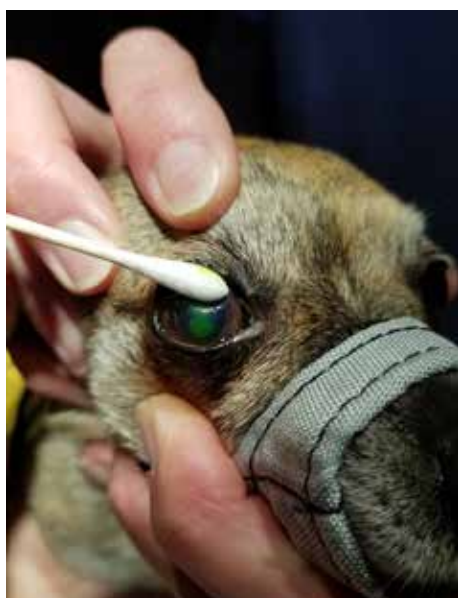
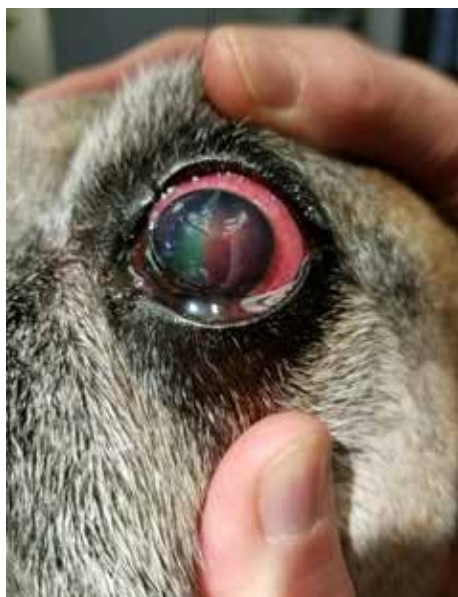
Figure 1 (top): Image of an eye with a spontaneous chronic corneal epithelial defect (SCCED) stained with fluorescein dye. Note the fluorescein dye undermining the edges of the epithelial layer and the diagnostic “lip” of loose epithelium.

Figure 2 (bottom): Image of an eye with a spontaneous chronic corneal epithelial defect (SCCED) stained with fluorescein dye. Corneal debridement is being performed with a sterile cotton swab prior to performing diamond burr keratotomy.

other important considerations include whether the cause could be sharp or blunt trauma, (foreign body, exposure, eyelash or eyelid abnormalities), infectious (bacterial, viral, fungal), chemical (soaps, flea sprays, etc.), associated with cellular or metabolic corneal stromal infiltrates (calcium, neutrophils) endothelial abnormalities (endothelial cell dystrophy, bullous keratopathy), or immune mediated (Dry eye, facial nerve paralysis, Terriers Marginal degeneration).

Spontaneous Chronic Corneal Epithelial Defect

A spontaneous chronic corneal epithelial defect (SCCED) previously referred to as indolent ulcer, “Boxer ulcer,” refractory corneal erosion, or rodent ulcer, is known as a superficial corneal ulcer that heals poorly or slowly and tends to recur despite conventional treatment. By clinical definition, an indolent ulcer is a corneal ulcer that has been present for a duration of at least three weeks. A SCCED invariably occurs in middle-aged to elderly dogs, and can develop in all breeds, although some breeds are more frequently affected, including the Boxer (the breed in which this condition was initially described) and the Golden Retriever. With advancing age, a hyalinized acellular zone (HAZ) develops in the superficial portion of the anterior corneal stroma which prevents proper adhesion of the epithelial layer of cornea to the underlying stroma, a predisposing factor for development of a SCCED.

A SCCED is described clinically as a superficial corneal defect involving only the corneal epithelium (there is no loss of corneal stromal tissue). This chronic superficial corneal ulceration has a peripheral edge of poorly adherent epithelial tissue, which is easily identified by examination. A SCCED is typically located in the central or paracentral cornea, and has a characteristic non-adherent “lip” of epithelium located at the periphery of the ulcer (*Figure 1*). When fluorescein dye is applied to the cornea, immediately the

exposed stroma retains fluorescein dye and is highlighted, however an enlarging area of fluorescein dye retention can be observed around the periphery of the ulcer as fluorescein undermines the non-adherent epithelial edges. Many SCCED’s are never accompanied by stromal vascularization, but if vascularization occurs the corneal stroma may or may not develop granulation tissue.

Medical treatment alone is unlikely to result in healing of a SCCED since the epithelium generally will not adhere completely to the underlying stroma while this HAZ is present. Treatment for a SCCED requires surgical removal of or penetration through the HAZ. Numerous techniques have been described to treat a SCCED including epithelial debridement, linear or grid keratotomy, multiple punctate keratotomy, superficial lamellar keratectomy, thermokeratoplasty (heat treatment), chemical debridement, cyanoacrylate tissue adhesive, and diamond burr debridement keratectomy.

Diamond burr debridement is a very effective and beneficial method to remove the HAZ. The diamond burr debridement technique is a more contemporary and preferred method of treatment for SCCED because it does not result in stromal scar formation, unlike other treatment methods. The procedure is performed using topical anesthetic with the patient awake. Non-adherent epithelial edges are debrided using a dry cotton swab—it is important that all loose epithelium be removed (*Figure 2*). It is important to note that normal epithelium overlying normal corneal stroma cannot be easily debrided because it is firmly adhered to the underlying corneal stroma. If the epithelium can be easily debrided, it is not normal and should be removed. Following debridement with a cotton swab, a battery powered, high-speed, low-torque rotating shaft instrument fitted with a mild diamond burr is used to perform the procedure (*Figure 3*). The rotating burr is pressed lightly against the affected ulcerated cornea and is moved back and forth to remove the HAZ. Post-operative care involves

Heartgard® *(ivermectin/pyrantel)* Plus

CHEWABLES

CAUTION: Federal (U.S.A.) law restricts this drug to use by or on the order of a licensed veterinarian.

INDICATIONS: For use in dogs to prevent canine heartworm disease by eliminating the tissue stage of heartworm larvae (*Dirofilaria immitis*) for a month (30 days) after infection and for the treatment and control of ascarids (*Toxocara canis*, *Toxascaris leonina*) and hookworms (*Ancylostoma caninum*, *Uncinaria stenocephala*, *Ancylostoma braziliense*).

DOSAGE: HEARTGARD® Plus (ivermectin/pyrantel) should be administered orally at monthly intervals at the recommended minimum dose level of 6 mcg of ivermectin per kilogram (2.72 mcg/lb) and 5 mg of pyrantel (as pamoate salt) per kg (2.27 mg/lb) of body weight. The recommended dosing schedule for prevention of canine heartworm disease and for the treatment and control of ascarids and hookworms is as follows:

Dog Weight	Chewables Per Month	Ivermectin Content	Pyrantel Content	Color Coding On Foil Backing and Carton
Up to 25 lb	1	68 mcg	57 mg	Blue
26 to 50 lb	1	136 mcg	114 mg	Green
51 to 100 lb	1	272 mcg	227 mg	Brown

HEARTGARD Plus is recommended for dogs 6 weeks of age and older.
For dogs over 100 lb use the appropriate combination of these chewables.

ADMINISTRATION: Remove only one chewable at a time from the foil-backed blister card. Return the card with the remaining chewables to its box to protect the product from light. Because most dogs find HEARTGARD Plus palatable, the product can be offered to the dog by hand. Alternatively, it may be added intact to a small amount of dog food. The chewable should be administered in a manner that encourages the dog to chew, rather than to swallow without chewing. Chewables may be broken into pieces and fed to dogs that normally swallow treats whole.

Care should be taken that the dog consumes the complete dose, and treated animals should be observed for a few minutes after administration to ensure that part of the dose is not lost or rejected. If it is suspected that any of the dose has been lost, redosing is recommended.

HEARTGARD Plus should be given at monthly intervals during the period of the year when mosquitoes (vectors), potentially carrying infective heartworm larvae, are active. The initial dose must be given within a month (30 days) after the dog's first exposure to mosquitoes. The final dose must be given within a month (30 days) after the dog's last exposure to mosquitoes.

When replacing another heartworm preventive product in a heartworm disease preventive program, the first dose of HEARTGARD Plus must be given within a month (30 days) of the last dose of the former medication.

If the interval between doses exceeds a month (30 days), the efficacy of ivermectin can be reduced. Therefore, for optimal performance, the chewable must be given once a month on or about the same day of the month. If treatment is delayed, whether by a few days or many, immediate treatment with HEARTGARD Plus and resumption of the recommended dosing regimen will minimize the opportunity for the development of adult heartworms.

Monthly treatment with HEARTGARD Plus also provides effective treatment and control of ascarids (*T. canis*, *T. leonina*) and hookworms (*A. caninum*, *U. stenocephala*, *A. braziliense*). Clients should be advised of measures to be taken to prevent reinfection with intestinal parasites.

EFFICACY: HEARTGARD Plus Chewables, given orally using the recommended dose and regimen, are effective against the tissue larval stage of *D. immitis* for a month (30 days) after infection and, as a result, prevent the development of the adult stage. HEARTGARD Plus Chewables are also effective against canine ascarids (*T. canis*, *T. leonina*) and hookworms (*A. caninum*, *U. stenocephala*, *A. braziliense*).

ACCEPTABILITY: In acceptability and field trials, HEARTGARD Plus was shown to be an acceptable oral dosage form that was consumed at first offering by the majority of dogs.

PRECAUTIONS: All dogs should be tested for existing heartworm infection before starting treatment with HEARTGARD Plus which is not effective against adult *D. immitis*. Infected dogs must be treated to remove adult heartworms and microfilariae before initiating a program with HEARTGARD Plus.

While some microfilariae may be killed by the ivermectin in HEARTGARD Plus at the recommended dose level, HEARTGARD Plus is not effective for microfilariae clearance. A mild hypersensitivity-type reaction, presumably due to dead or dying microfilariae and particularly involving a transient diarrhea, has been observed in clinical trials with ivermectin alone after treatment of some dogs that have circulating microfilariae.

Keep this and all drugs out of the reach of children.

In case of ingestion by humans, clients should be advised to contact a physician immediately. Physicians may contact a Poison Control Center for advice concerning cases of ingestion by humans.

Store between 68°F - 77°F (20°C - 25°C). Excursions between 59°F - 86°F (15°C - 30°C) are permitted. Protect product from light.

ADVERSE REACTIONS: In clinical field trials with HEARTGARD Plus, vomiting or diarrhea within 24 hours of dosing was rarely observed (1.1% of administered doses). The following adverse reactions have been reported following the use of HEARTGARD: Depression/lethargy, vomiting, anorexia, diarrhea, mydriasis, ataxia, staggering, convulsions and hypersalivation.

SAFETY: HEARTGARD Plus has been shown to be bioequivalent to HEARTGARD, with respect to the bioavailability of ivermectin. The dose regimens of HEARTGARD Plus and HEARTGARD are the same with regard to ivermectin (6 mcg/kg). Studies with ivermectin indicate that certain dogs of the Collie breed are more sensitive to the effects of ivermectin administered at elevated dose levels (more than 16 times the target use level) than dogs of other breeds. At elevated doses, sensitive dogs showed adverse reactions which included mydriasis, depression, ataxia, tremors, drooling, paresis, recumbency, excitability, stupor, coma and death. HEARTGARD demonstrated no signs of toxicity at 10 times the recommended dose (60 mcg/kg) in sensitive Collies. Results of these trials and bioequivalency studies, support the safety of HEARTGARD products in dogs, including Collies, when used as recommended.

HEARTGARD Plus has shown a wide margin of safety at the recommended dose level in dogs, including pregnant or breeding bitches, stud dogs and puppies aged 6 or more weeks. In clinical trials, many commonly used flea collars, dips, shampoos, anthelmintics, antibiotics, vaccines and steroid preparations have been administered with HEARTGARD Plus in a heartworm disease prevention program.

In one trial, where some pups had parvovirus, there was a marginal reduction in efficacy against intestinal nematodes, possibly due to a change in intestinal transit time.

HOW SUPPLIED: HEARTGARD Plus is available in three dosage strengths (See DOSAGE section) for dogs of different weights. Each strength comes in convenient cartons of 6 and 12 chewables.

For customer service, please contact Merial at 1-888-637-4251.

©HEARTGARD and the Dog & Hand logo are registered trademarks of Merial.
©2015 Merial, Inc., Duluth, GA. All rights reserved.

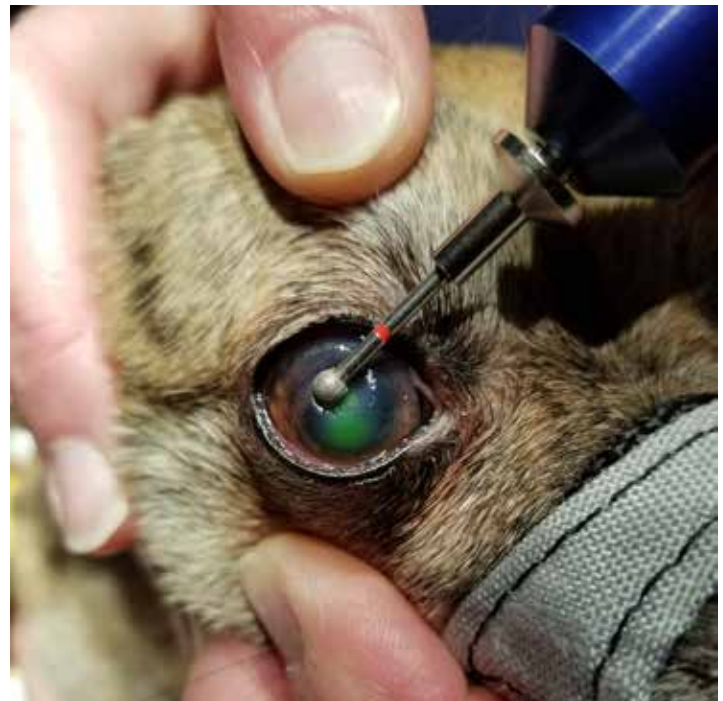

Figure 3: Image of the same eye shown in Figure 2 while performing diamond burr keratotomy.

administration of a topical broad-spectrum antibiotic, systemic and topical nonsteroidal anti-inflammatory medications, and topical and systemic pain medications.

As with treatment of all corneal ulcers, the exception being immune-mediated ulcers, use of topical corticosteroids should be avoided. Topical Atropine may be administered once daily for 3-5 days to reduce ocular pain, but is contraindicated in patients with Keratoconjunctivitis Sicca (Dry Eye) and patients with or predisposed to develop glaucoma. A protective collar should also be worn by the patient at all times to prevent self-trauma to the healing cornea until the ulcer has healed. Since SCCED is an age-related ulcer, owners should be informed that SCCED is usually a bilateral condition, and the fellow eye usually develops a SCCED within one year.

Other surgical treatment alternatives include grid keratotomy and multiple punctate keratotomy which are performed using a 25 gauge needle, and involve creating superficial linear incisions in a crosshatch grid pattern (linear grid keratotomy) or creating multiple punctures (multiple punctate keratotomy) through the basement membrane and into the anterior corneal stroma. Superficial lamellar keratectomy can also be performed but is infrequently necessary due to the high success rate of the diamond burr debridement. Lamellar keratectomy removes the superficial layers of the anterior corneal stroma and is generally recommended as a last resort treatment for SCCED's that fail to heal with other therapies. This procedure requires general anesthesia, and is a more expensive and demanding micro surgical procedure. Both the diamond burr and

grid keratotomy procedures are performed with topical anesthetic only, and since the patient is generally middle aged to geriatric, this eliminates risks and costs associated with general anesthesia therefore, appealing to owners.

Stromal Ulcers

Determining the depth of a corneal stromal ulcer is critical since surgical treatment is usually indicated for ulcers involving the deeper layers of the corneal stroma. Superficial stromal ulcers typically have well defined margins, with minimal changes in corneal contour and topography. Superficial stromal ulcers may be treated medically and conservatively, with a topical broad spectrum antibiotic, ocular pain management, and a protective collar. Re-evaluation is recommended every 3-5 days until re-epithelialization is complete.

If an ulcer involves the deep stroma or greater than half corneal thickness, the cornea is fragile and is at risk to perforate—therefore it should be handled carefully. It is critical to avoid placing any external pressure on the eye that might cause the eye to rupture. If an ulcer is progressive, regardless of whether the stromal ulcer is superficial or deep, the ulcer should be treated aggressively, as this is potentially a vision and globe threatening abnormality. If the ulcer is non progressive (e.g., collagenolysis [“melting”] is not evident) and uncomplicated (e.g., there are no cellular infiltrates in the cornea),

and it is not infected, it may be treated conservatively as described above for a superficial stromal ulcer.

Stromal ulcers may have inflammatory cellular infiltrates within the stroma which produce matrix metalloproteinases (MMP’s). These are enzymes that degrade the extracellular matrix resulting in rapid collagen degradation, or collagenolysis (a “melting” ulcer) (Figure 4). When an ulcer becomes infected by certain bacteria (especially *Pseudomonas* spp, *Staphylococcus* spp, and *Streptococcus* spp.) and from MMPs that are over-expressed by corneal epithelial cells, keratocytes and neutrophils present in tear film or that have infiltrated the corneal stroma, and cause destruction of the corneal extracellular matrix, resulting in rapid collagen degradation (collagenolysis) and loss of the entire thickness of the stroma within 4-24 hours. Bacteria, specifically *Pseudomonas* spp, also produce MMP which degrade corneal stromal collagen. Stromal ulcers that are infected and “melting” will have gelatinous margins and the stroma may have a mucoid appearance that may remain attached to the cornea and may not be easily removed (Figures 5 and 6). Treatment with a topical antibiotic that penetrates into corneal tissue (a fluoroquinolone) is recommended every hour in an attempt to cease bacterial infection. Doxycycline or minocycline administered orally have the property to stop collagenolysis (e.g. “melting”) by impairing MMP-2 and

MMP-9 activity. Topical autogenous serum contains alpha-2 macroglobulin, which also may arrest collagenolysis by blocking MMP-9 activity. Topical atropine may also be used to prevent ciliary muscle spasm which alleviates ocular pain, helps prevent anterior uveitis, and prevents formation of posterior synechia. A protective collar should be placed to prevent any self-trauma to the globe. Re-evaluation is recommended with-in 24-48 hours. It is important for owners to understand the severity of deep or progressive corneal ulceration and if the ulcer does not respond well to aggressive medical treatment, surgery (conjunctival graft) may be required to save the globe.

Depending on the size and depth of the ulcer, and whether vascularization of the corneal stroma is present, a conjunctival graft may be necessary to provide tectonic support in order to prevent rupture, and to provide a vascular supply to favor healing. A conjunctival graft consists of transposing a thin layer of only conjunctival membrane tissue onto the cornea to provide tectonic support and to provide a vascular tissue supply to aid in healing. Surgically transposing a vascular supply (conjunctival graft) to the ulcer also provides leukocytes and antibodies to provide antimicrobial and anti-collagenase effects, as well as delivers systemic antibiotics to the site. Third eyelid flaps are never recommended and are contraindicated for treatment of infected, deep or complicated ulcers since they prevent direct visualization and re-

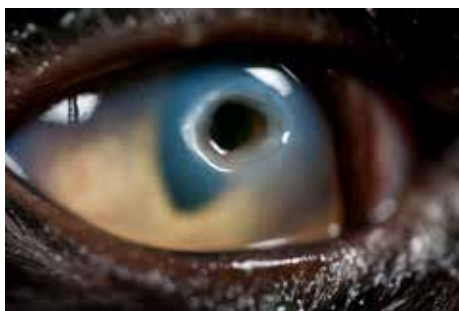

Figure 4: An image of a “melting” corneal ulcer. Note deep neovascularization completely surrounding the ulcerated cornea with degenerated stromal collagen which masquerades as a mucoid discharge.

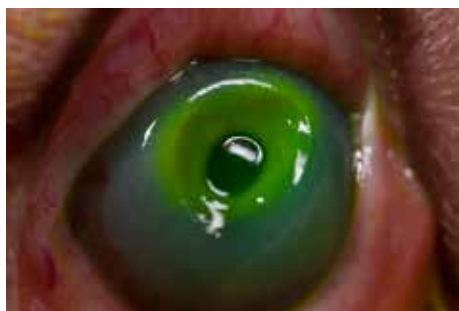

Figure 5: An image of a corneal ulcer with keratomalacia (a “melting” corneal ulcer). The corneal epithelium has been lost and the stroma, which is composed of collagen, has degenerated.



Figure 6: An image of a protruding corneal bulla (a blister) that is retaining fluorescein dye. This must be differentiated from a protruding descemetocele which will not retain fluorescein dye. Corneal bullae are treated medically, whereas descemetocele requires surgical repair.

evaluation of the healing process. Placing a third eyelid flap can also induce unnecessary pressure on the globe, which can result in perforation of a deep stromal ulcer or a descemetocele.

A descemetocele is a deep ulcer in which the corneal stroma is completely absent and Descemet's membrane is exposed. Descemet's membrane will not stain positive with fluorescein dye, as there is no stroma present in that area to retain fluorescein dye. A descemetocele will have an excavated, crater-like appearance, indicating loss of stromal tissue. However, the deepest portion of the ulcer (Descemet's membrane) will appear clear (it will lack corneal edema) or will appear black over the pupil. Note that the periphery of the ulcer where corneal stromal tissue is present will retain fluorescein dye as long as the stroma in this location has not epithelialized, and will appear as a "target" (Figures 7 and 8). A descemetocele requires surgery for the highest success rate at saving vision. Surgical placement of multilaminar collagen matrix (BioSist) with an onlay conjunctival graft may be required in order to seal the tissue and provide vascularization to the area (Figures 8 and 9). When the defect occurs within the visual axis, and if adequate normal corneal tissue is located adjacent to the ulcerated area, corneoconjunctival lamellar transposition can be performed to restore a clear visual axis. Third eyelid flaps are never indicated and often result in perforation of the globe. When a descemetocele has perforated, iris tissue may prolapse through the defect and hyphema and/or fibrin may be present in the anterior chamber. Prolapsed iris tissue may require amputation before proceeding with multilaminar collagen matrix and placement of a conjunctival graft. Post-operative medications should include topical and systemic antibiotics, and systemic non-steroidal anti-inflammatories (NSAID) and analgesics. The pet must wear a protective collar at all times and re-evaluation is typically within 1 to 5 days. If surgery is not an option (due to budget constraints or

anesthetic risks, etc) the eye is very fragile and is at risk for perforation. If perforation does not occur, later in the healing process corneal epithelium migrates over the corneal stroma and Descemet's membrane and forms a corneal facet (divot). This will be evident in the corneal stroma, but since corneal stroma and Descemet's membrane are covered by corneal epithelium, fluorescein dye will not be retained. A "pooling" effect of fluorescein dye within the facet will occur, but can be washed away. A facet requires no treatment and will continue to fill in overtime.

Medication Recommendations for Corneal Ulcers

Ulceration of the cornea eliminates the corneal epithelium (barrier) and permits surface bacterial attachment to the corneal stroma—a necessary requisite to establishing bacterial infection. Despite corneal stromal exposure, most corneal ulcers are not infected. Only two indications exist for administering a topical antibiotic when corneal ulceration exists: 1) to prevent infection from occurring, or 2) to treat infection. The difference between preventing infection and treating infection is vastly different regarding the selection of an appropriate topical antibiotic. Some topical antibiotics are more toxic to the corneal epithelium and delay wound healing (gentamicin, ciprofloxacin) whereas others are far less toxic and minimally delay corneal wound healing (tobramycin, ofloxacin). When an ulcer is not infected or complicated, a broad-spectrum topical antibiotic that does not penetrate into corneal tissue (tobramycin, bacitracin-polymyxin-gramacidin) is recommended to prevent infection. When an ulcer is complicated or infected, a topical antibiotic that penetrates deep into corneal stromal tissue is recommended (ofloxacin, marbofloxacin). Treatment of a corneal ulcer with a topical antibiotic will not speed re-epithelialization or healing; likewise, changing topical antibiotic treatment because an ulcer has not healed

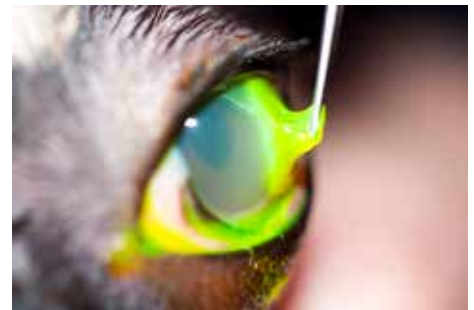

Figure 7: An image of a cornea with a descemetocele with loss of corneal stromal collagen.

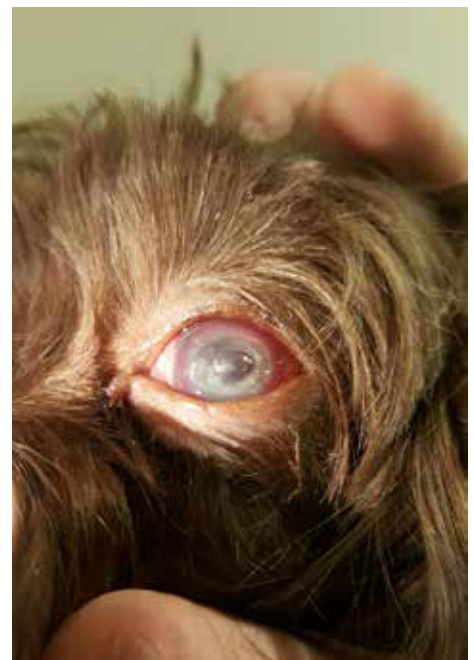

Figure 8: An image of a descemetocele stained with fluorescein dye. Note the corneal stroma retaining fluorescein dye and absence of fluorescein dye retention by exposed Descemet's membrane. Exposed corneal stroma also retains tear fluid, resulting in corneal edema.

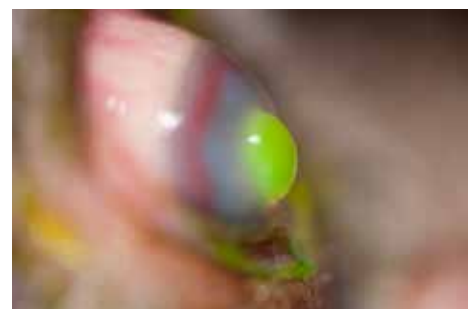

Figure 9: A descemetocele which is protruding. This occurs when Descemet's membrane is pushed outward by intraocular pressure. Debriding an ulcer with a descemetocele can result in perforation of the globe and expulsion of aqueous humor and anterior uveal tissues.



Visit VetMedTeam.com
and log in with your
Vet Med Team Profile.

will also not speed healing. Use of topical corticosteroids or topical anesthetics to treat a corneal ulcer is never advised and is unequivocally contraindicated. Topical corticosteroids delay epithelial healing, can potentiate “melting” (collagenolysis) and cause ocular immunosuppression which can favor infection. Topical anesthetics can also prevent epithelial healing.

In conclusion, corneal ulcers occur frequently in dogs and although a superficial, uncomplicated ulcer may likely heal without medical attention, a complicated ulcer requires optimal knowledge and management if the affected eye is to be saved. Proper treatment of an ulcer requires knowledge of common causes of ulceration, expected healing times, types and severity of ulceration, general medical therapy for each type of ulcer, and knowledge of when surgery is indicated. In an ulcer that is not healing with current medical therapy, the underlying cause may still be present or the cause of the ulcer may have been misdiagnosed. When an ulcer has become infected and is melting, or when a superficial ulcer fails to heal, referral to a veterinary ophthalmologist is advised. The decision to refer to a specialist may mean the difference of preserving or restoring vision and/or salvage of the globe. **J**

REFERENCES

1. Ramsey DT. *Veterinary Ophthalmology Lecture Notes*. 4th ed. University Printing, 1999.
2. Martin CL. *Ophthalmic Disease in Veterinary Medicine*. Manson Publishing Ltd; 2010
3. Maggs DJ, Miller PE, Ofri R. *Slatter's Fundamentals of Veterinary Ophthalmology*. 4th ed. Saunders Elsevier Inc. 2008.
4. Gelatt KN, Gilger BC, Kern TJ. *Veterinary Ophthalmology*. 5th ed. John Wiley & Sons Inc. 2013.
5. Spiess BM, Pot SA, Florin M, Hafezi F. Corneal collagen cross-linking for the treatment of melting keratitis in cats and dogs: a pilot study. *The official Journal of the American College of Veterinary Ophthalmologists*. 2014; volume 17 number 1.

*Photo credits: David Ramsey

SARA GRABIEL-DUNCAN, BS, LVT, VTS

Sara Grabiél-Duncan, BS, LVT, VTS, is a Veterinary Technician Specialist in ophthalmology who has been in veterinary ophthalmology exclusively for over ten years. She has been a Licensed Veterinary Technician since 2010 and holds a Bachelor of Science degree from Michigan State University. Sara is married and has two beautiful children, a dog and two cats. She enjoys traveling, camping and hiking with her family.

LET'S REVIEW...

1. **Name the layer of the cornea where a superficial ulcer occurs:**
 - a. Corneal stroma
 - b. Tear film
 - c. Corneal epithelium
 - d. Corneal endothelium
2. **A deep divot in the cornea is observed, however it is fluorescein negative and the patient is comfortable. This is because;**
 - a. Corneal epithelium has re-epithelialized over the deep area of ulceration and is now considered to be a corneal facet
 - b. This is a descemetocele and requires surgical repair
 - c. Fluorescein stain will not stain the corneal stroma
 - d. This type of ulcer requires debridement
3. **A 10 year old boxer presents with a superficial non healing ulcer of 3 weeks duration. This type of ulcer requires which of the following?**
 - a. Medical treatment alone with a different topical antibiotic and protective collar
 - b. A third eyelid flap
 - c. Corneal debridement with sterile cotton swabs
 - d. Corneal debridement and diamond burr keratotomy
4. **Which type of corneal ulcer is affected negatively by MMPs?**
 - a. A SCCED (spontaneous chronic corneal epithelial defect)
 - b. A descemetocele
 - c. A “melting” corneal ulcer
 - d. A corneal facet
5. **Corneal debridement and/or diamond burr keratotomy should never be performed on which of the following;**
 - a. A deep complicated ulcer
 - b. A young dog
 - c. A middle aged to older dog with a superficial ulcer
 - d. A & B